

Inadvertent Injection of Sodium Tetradecyl Sulfate During Placement of Mental Nerve Block: Discussion of Management and Outcome

DAVID A. KIKEN, MD AND MITCHEL P. GOLDMAN, MD*

Dr. Goldman is a consultant with Bioniche Pharma Ltd., manufacturer of Sotradecol, and Angiodynamics Inc., distributor of Sotradecol.

Sclerotherapy involves the injection of a foreign substance into the lumen of a vessel to destroy the wall of that vessel and lead to its occlusion. Sodium tetradecyl sulfate (STS) is a detergent solution commonly used in sclerotherapy to treat varicose and telangiectatic veins. Its actions lead to destruction of endothelial cells.^{1,2} We report a case of the inadvertent injection of STS into the mental nerve of a patient who was supposed to be treated with an anesthetic agent for a mental nerve block before hyaluronic acid treatment. We discuss the case presentation, management, and outcome.

Case Report

A 39-year-old woman presented to a clinic elsewhere for hyaluronic acid treatment. Local anesthesia consisting of 1% lidocaine with epinephrine and bicarbonate was used to anesthetize the right mental nerve. Inadvertently, 2 mL of sodium tetradecyl sulfate 0.2% was injected into the left mental nerve. The patient complained of mild tenderness to the left mental nerve. The site was then infiltrated with 7 mL of normal saline and 10 U of hyaluronidase. On Day 2, the patient complained of moderate pain but denied any paresthesia. On physical examination, she had a 2- × 2-cm mild blue discoloration at the site of injection. Pentoxifylline 400 mg three times a day was started, and cephalexin 250 mg four times a day for 7 days was prescribed. On Day 3, the patient

called complaining of severe pain and increased discoloration. Her physical examination showed yellow–blue discoloration. (Figure 1). On Day 4, hyperbaric oxygen treatment was started. She tolerated two treatments (2 hours each at 2 atm for 2 consecutive days) well without complications. On Day 7, she returned to clinic. Her pain was completely resolved, but a yellow–blue discoloration persisted (Figure 2). On Day 14, she returned to clinic with her discoloration completely resolved (Figure 3).

Discussion

Inadvertent injection or extravasation of STS can result in cutaneous necrosis and nerve damage. In this patient, the error was fortunately recognized early, and she was promptly treated with copious amounts of normal saline and hyaluronidase. Pentoxifylline was started on Day 2 to help prevent necrosis. Hyperbaric oxygen therapy was also started once she began to complain of pain and worsening discoloration.

Cutaneous necrosis is a known and relatively uncommon yet feared side effect that may occur after the injection of a sclerosing agent.³ Inadvertent subcutaneous injection of up to 1 mL of hypertonic saline 23.4% in lieu of lidocaine into the neck or cheek has been reported to result in no adverse

*Both authors are affiliated with the Division of Dermatology, University of California, San Diego, California

© 2009 by the American Society for Dermatologic Surgery, Inc. • Published by Wiley Periodicals, Inc. • ISSN: 1076-0512 • *Dermatol Surg* 2009;35:2042–2045 • DOI: 10.1111/j.1524-4725.2009.01331.x

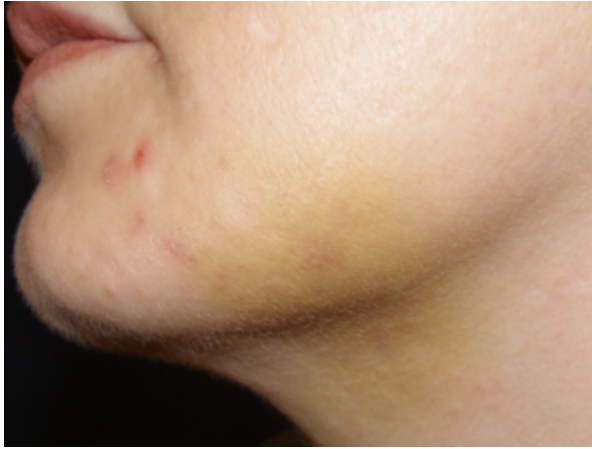

Figure 1. Examination on day 3.

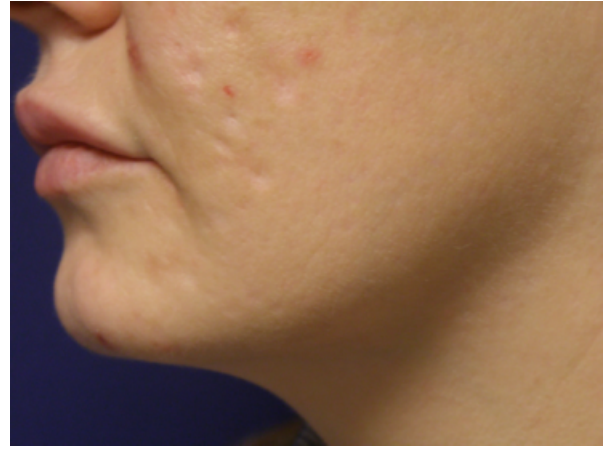

Figure 3. Examination on day 14.

sequelae.⁴ In this case, cutaneous necrosis was likely avoided by rapid physiologic dilution of the hypertonic saline. Certain sclerosants are associated with a lower risk of cutaneous necrosis. Duffy has reported injecting 0.4 mL of 3% pol into his own forearm without ulceration (Figure 4).^{5,6} Injection of STS into a nerve has also been reported to be painful and can result in anesthesia and sometimes permanent nerve impairment.⁷ Multiple cases of inadvertent injection into a nerve have been reported with resulting variable degrees of nerve paralysis or paresis.⁸

Tissue necrosis can occur with any sclerosant, but it is more commonly associated with high concentrations of sclerosants and in particular with certain

types of sclerosants. It is common with hypertonic saline and high-strength sodium tetradecyl sulfate. Sodium tetradecyl sulfate 1% will cause contact ulceration, whereas sodium tetradecyl sulfate 0.2% is dilute and will not cause contact ulceration. Tissue

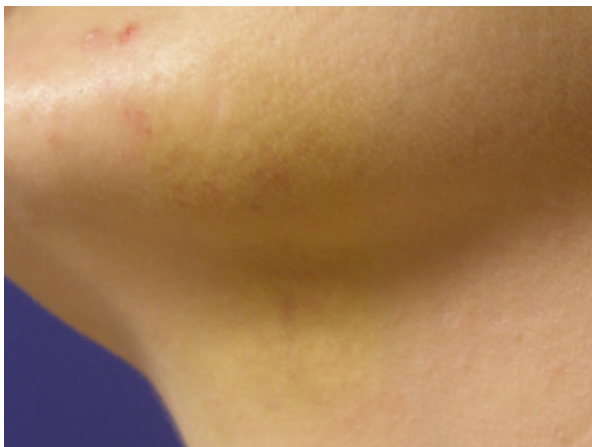

Figure 2. Examination on day 7.

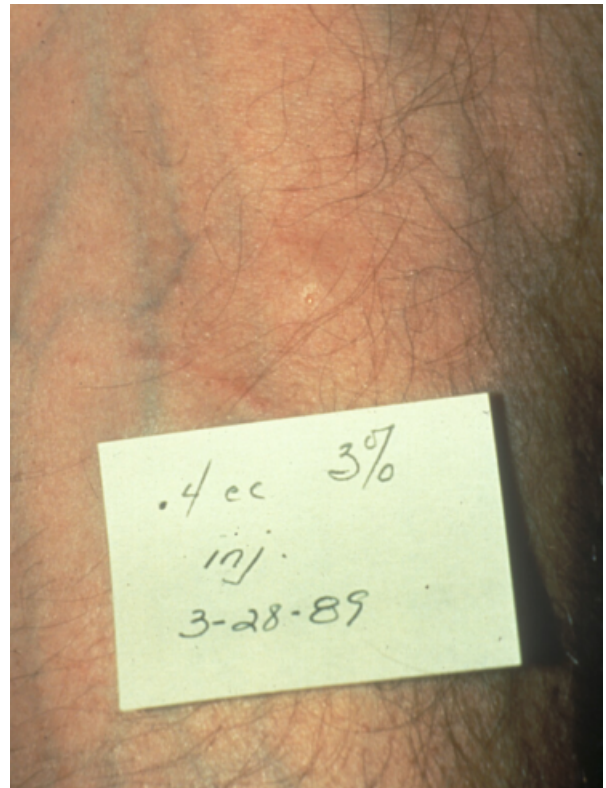


Figure 4. Duffy injected 0.4 mL of 3% pol into his own forearm without ulceration.

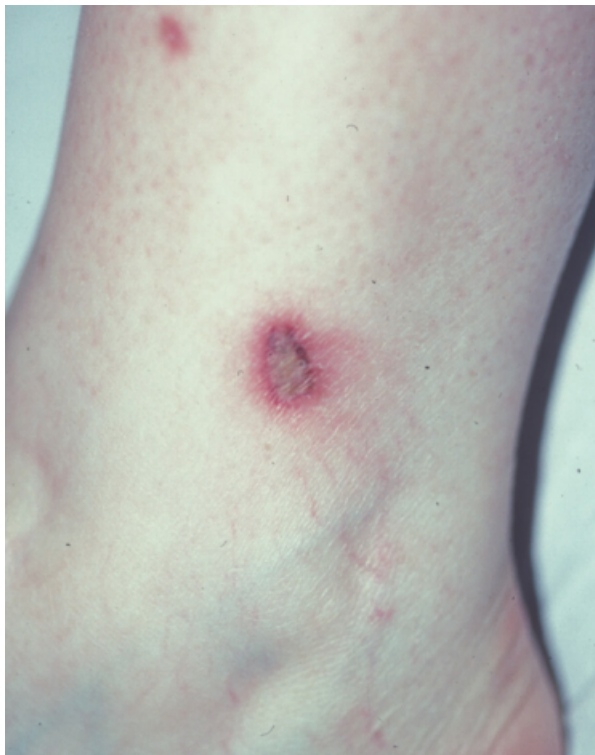

Figure 5. Tissue necrosis after sclerotherapy for telangiectasia below the ankle.

necrosis also occurs more commonly after sclerotherapy for vessels involving the medial malleoli, telangiectasia below the ankle (Figure 5), and on the face (Figure 6).⁸⁻¹⁰ Nevertheless, prompt treatment is critical to avoid or lessen the potential for necrosis and nerve damage.

Management of extravasated sclerosing solution includes prompt dilution of the site. Dilution with hyaluronidase in normal saline has been shown to limit the extent and prevent cutaneous necrosis from 3% STS.¹¹ Hyaluronidase helps to prevent tissue necrosis through accelerated dilution, cellular stabilization, and improved wound repair,¹²⁻¹⁵ although at least one study has shown that hyaluronidase solution must be injected within 60 minutes of extravasation to be effective.¹⁶ Although hyaluronidase is supposedly ineffective when used more than 60 minutes after extravasation, it has been shown to be of value in avoiding tissue necrosis after the use of hyaluronic acid¹⁷ even when the treatment had been

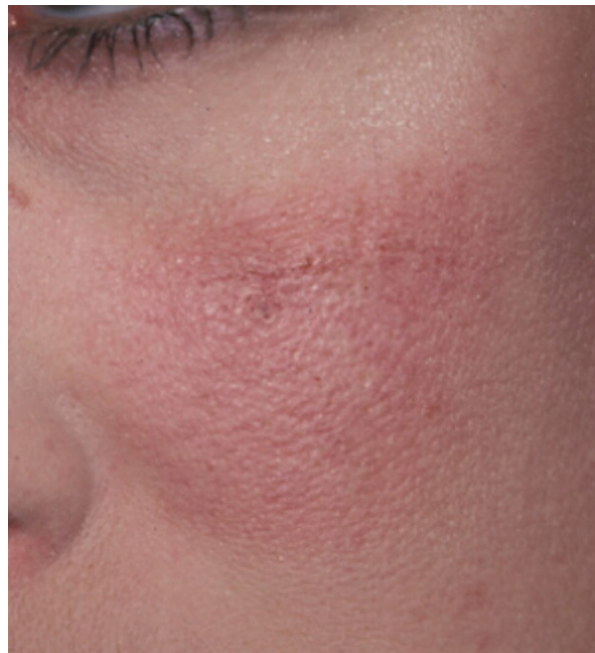

Figure 6. Tissue necrosis occurring after sclerotherapy for vessels on the face.

performed several days before. Hyaluronidase and a protocol for its employment should be immediately accessible to anyone who uses dermal filling agents or performs sclerotherapy. Hyaluronidase (Vitrise is available at Ista Pharmaceuticals, Inc., Irvine, CA). It must be kept refrigerated and should not be used in patients with allergies to bee stings; skin test should be performed before use.

Pentoxifylline also shows promise in the treatment of extravasated sclerosing solution to prevent cutaneous necrosis. Pentoxifylline decreases tissue injury of ischemia-reperfusion by increasing the deformability of red blood cells and decreasing blood viscosity.¹⁸ Hyperbaric oxygen treatment has become a mainstay for the treatment of chronic and nonhealing wounds. It has been shown to promote wound healing by increasing tissue oxygen and stimulating angiogenesis, fibroblast proliferation, and collagen synthesis.^{19,20} Hyperbaric oxygen therapy was used successfully in this patient to help reverse her deteriorating condition and avoid ulceration or permanent nerve damage.




Figure 7. Colored gummed stickers attached to the piston of the syringes identify the presence and concentration of sclerosants in the syringes.

In summary, inadvertent injection of a sclerosing agent has the potential for a devastating outcome. Safeguards must be in place to avoid this potentially disastrous problem. A simple way to clearly identify sclerosant-filled syringes is exemplified in Figure 7, in which colored gummed stickers attached to the piston of the syringes identify the presence and concentration of sclerosants in the syringes.

Acknowledgment The authors would like to thank Dr. David Duffy for his helpful review of this manuscript.

References

- Duffy DM. Small vessel sclerotherapy: an overview. In: Callen JP, et al., editors. *Advances in dermatology*, Vol. 3. Chicago, IL: Mosby; 1988.
- Goldman MP, Bergan JJ, Guex JJ. *Sclerotherapy: Treatment of Varicose and Telangiectatic Leg Veins*, Vol. 4. Maryland Heights, MO: Elsevier; 2007.
- Guex JJ, Allaert FA, Gillet JL, Chleir F. Immediate and midterm complications of sclerotherapy: report of a prospective multicenter registry of 12,173 sclerotherapy sessions. *Dermatol Surg* 2005;31:123.
- Eaglstein W. Inadvertent intracutaneous injection with hypertonic saline (23.4%) in two patients without complications. *J Dermatol Surg Oncol* 1990;16:878.
- Duffy DM. Setting up a vein treatment center: incorporating sclerotherapy into the dermatologic practice. *Semin Dermatol* 1993;12:150.
- Duffy DM. Cutaneous necrosis following sclerotherapy. *J Aesth Dermatol Cosmet Surg* 1999;1:157.
- Browse NL, Burnard KG, Thomas ML. *Diseases of the veins: pathology, diagnosis, and treatment*. London: Edward Arnold; 1988.
- Duffy D. Techniques of small vessel sclerotherapy. In: Goldman M., Weiss R., Bergan J., editors. *Varicose veins and telangiectasia: diagnosis and treatment* Ch. 24. 2nd edition. Quality Medical Publishing; 1999. p. 518–47.
- Murad Alam, Tri H. Nguyen, Duffy D. Procedures in Cosmetic Dermatology; Treatment of Leg Veins. In: *Sclerotherapy*. Amsterdam: Elsevier Inc.; 2006. p. 71–106.
- Biegeleisen K, Neilsen RD, O'Shaughnessy A. Inadvertent intra-arterial injection complicating ordinary and ultrasound-guided sclerotherapy. *J Dermatol Surg Oncol* 1993;19:953.
- Zimmet SE. The prevention of cutaneous necrosis following extravasation of hypertonic saline and sodium tetradecyl sulfate. *J Dermatol Surg Oncol* 1993;19:641.
- Senk KE. Management of intravenous extravasation. *Infusion* 1981;5:77.
- Laurie SWS, Wilson L, Kernahan A, et al. Intravenous extravasation injuries: the effectiveness of hyaluronidase in their treatment. *Ann Plast Surg* 1984;13:191.
- Grossman JA, et al. The effects of hyaluronidase and dimethyl sulfoxide (DMSO) on experimental flap survival. *Ann Plast Surg* 1983;11:222.
- Lorenz HP, Adzick NS. Scarless skin wound repair in the fetus. *West J Med* 1993;159:350.
- Heckler FR, McCraw JB. Calcium-related cutaneous necrosis. *Plast Surg* 1976;27:553.
- Hirsch R. Necrosis following augmentation with hyaluronic acid and management with hyaluronidase. *Drugs Dermatol* 2007;6: 325–8.
- Adams JG Jr, Animesh D, Shukla SD, et al. Effect of pentoxifyline on tissue injury and platelet-activating factor production during ischemia-reperfusion injury. *J Vasc Surg* 1995;21:742–9.
- Feldmeier JJ. The hyperbaric oxygen therapy committee report UHMS. In: Feldmeier JJ, editor. *Hyperbaric oxygen 2003. Indications and results*. Maryland: Kensington; 2003. p. 87–100.
- Hampson NB, et al. *Hyperbaric Oxygen Therapy: 1999 Committee Report*. Kensington, MD: Undersea and Hyperbaric Medical Society, 1999.

Address correspondence and reprint requests to: David A. Kiken, MD, 616 South Orange Avenue, Unit 5G, Maplewood, New Jersey 07040, or e-mail: drkiken@alumni.upenn.edu